

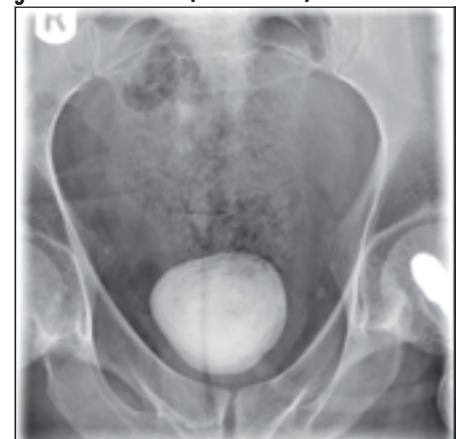
Giant bladder stone: making a rare complication

While awaiting elective surgery a man with multiple sclerosis presented to accident and emergency with acute kidney injury, secondary to bilateral

hydronephrosis caused by a giant obstructing bladder stone (Figure 1). Decompression with bilateral nephrostomies was performed, followed by interval open cystolithotomy and stone removal.

Acute kidney injury and renal impairment caused by bilateral hydronephrosis is a rare but potentially life-threatening complication of giant bladder stone.

Figure 1. Plain abdominal radiograph showing a giant bladder stone (52 x 53 mm).



Dr Mohamed I Abdulmajed is Core Surgical Trainee in Urology and **Mr Iqbal S Shergill** is Consultant Urological Surgeon in the Department of Urology, Wrexham Maelor Hospital, Betsi Cadwaladr University Health Board, Wrexham LL13 7TD

Correspondence to: Mr IS Shergill (Iqbal.Shergill@wales.nhs.uk)